



2 Forearm fractures

2.12 I Forearm shaft fractures – Treatment with a cast

Indication **All 22-A, 22-B and 22-C type fractures, excluding 22-B1.3, 22-B2.3**

1 Indications

The only adult forearm shaft fractures in which a satisfactory functional outcome can be expected after nonoperative treatment are A1.2 fractures which are undisplaced, minimally displaced (less than 50% translation, less than 10° angulation), or stably reduced, isolated ulnar fractures with no compromise of either radioulnar joint. According to Sarmiento et al, the more proximal the level of the fracture the higher the risk of impaired pronation. See:

- Mackay D, Wood L, Rangan A (2000) The treatment of isolated ulnar fractures in adults: a systematic review. *Injury*; 31(8): 565-70.

- Sarmiento A, Latta LL, Zych G, et al (1998) Isolated ulnar shaft fractures treated with functional braces. *J Orthop Trauma*; 12 (6): 420-3; discussion 423-4.
- Handoll HH, Pearce P (2009) Interventions for isolated diaphyseal fractures of the ulna in adults. *Cochrane Database Syst Rev*; Jul 8; (3): CD000523.

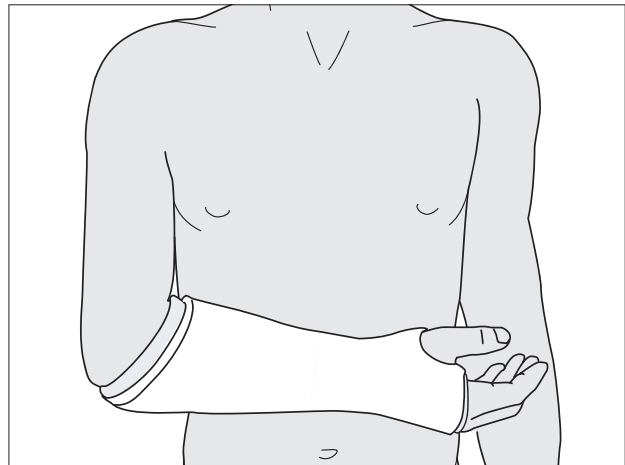
In all other cases, if nonoperative treatment is necessary because of severe soft-tissue compromise or the patient being unfit for surgery, the functional outcome will inevitably be suboptimal.

2 Treatment principles

The basic principles of nonoperative treatment of forearm shaft fractures are:

- 1) Except in 22-A1.2 fractures, both wrist and elbow joints must be included in the cast.

Note: Mackay et al. and Sarmiento & Latta suggest that in isolated ulnar fractures, above elbow splintage is not necessary.





2) If the elbow joint is included in the cast, it should be in 90° flexion.

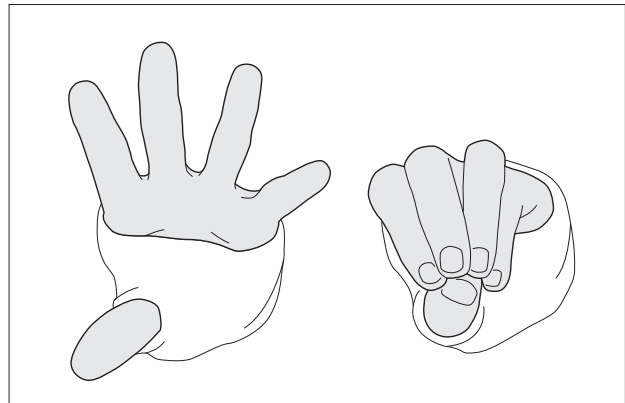
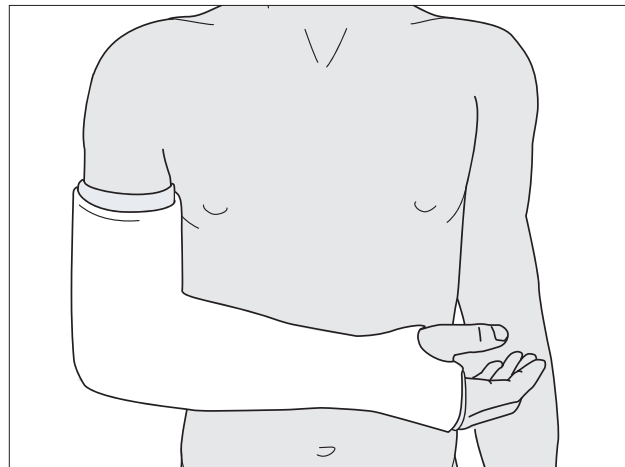
3) The general form of the forearm should be restored.

Note: For 22-A1.2 fractures, this is usually not required.

4) The cast should be well-padded and split along its whole length in any injury where progressive swelling is to be expected.

5) The cast should not extend beyond the proximal palmar flexor crease, in order to permit full flexion of the MCP joints of the fingers.

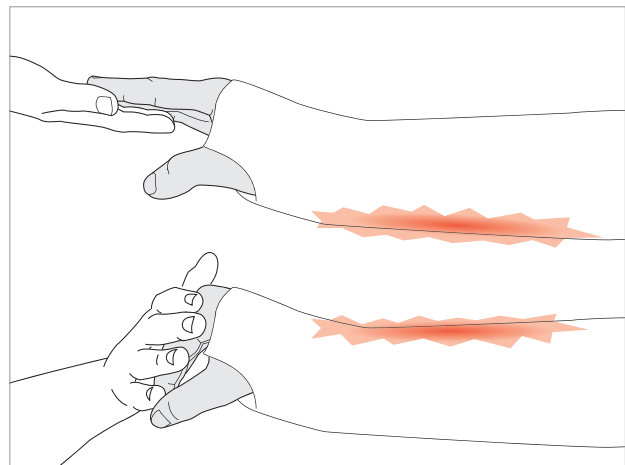
6) The thumb should not be included in the cast.



Sarmiento and Latta (Closed Functional Treatment of Fractures, Springer Verlag, 1981, p.384) recommend that the cast be applied with the arm suspended from Chinese fingers traps and the elbow at a right angle. This

results in a forearm posture of “relaxed supination”: they combine this with careful moulding anteroposteriorly in such a manner as to separate the two bones and tension the interosseous membrane.

Meticulous clinical observation for compartment syndrome must be undertaken. Watch out for increasing inappropriate pain, especially with passive stretching of the muscles of the affected compartment(s).





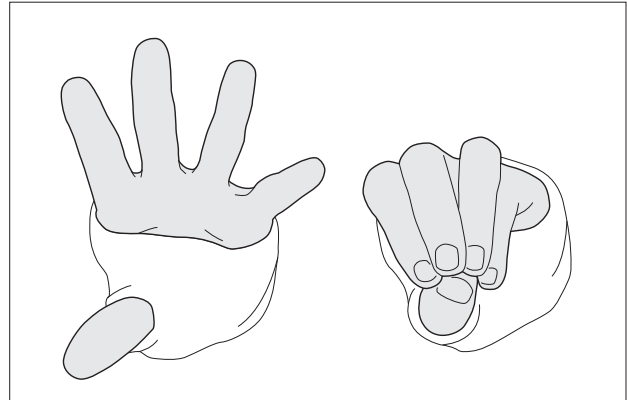
3 Aftercare following nonoperative treatment

3.1 Record of fracture alignment

Document fracture position radiographically after casting, for future reference.

3.2 Extension and flexion of the fingers

Start with finger exercises immediately after casting. Maintain elevation of the limb for 24 hours, paying special attention to pain, especially with passive extension and flexion to the fingers, which could indicate compartment syndrome.



3.3 Broad arm sling

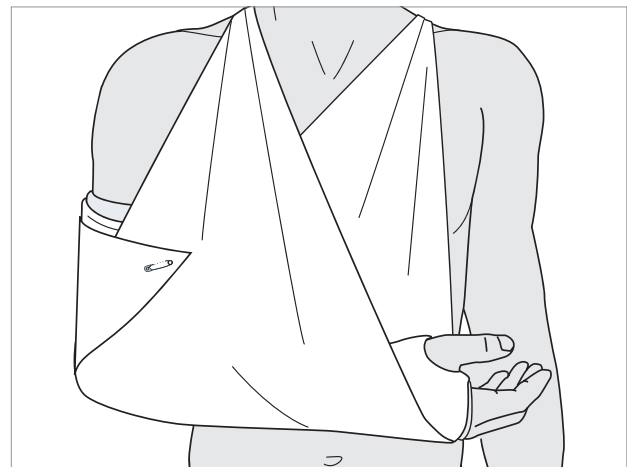
Generally, a broad arm sling is preferable to a collar and cuff sling.

The collar and cuff can induce ulnar bowing due to cast dropping in the forearm, when the forearm muscles waste.

The ulnar bowing is produced because the wrist is still firmly held by the collar and cuff.

In 22-A1.2 fractures, the broad arm sling is used to support the weight of the cast for the first 7-10 days. It is advisable to practice active elbow extension exercises out of the sling on a regular basis if a short arm cast is being used.

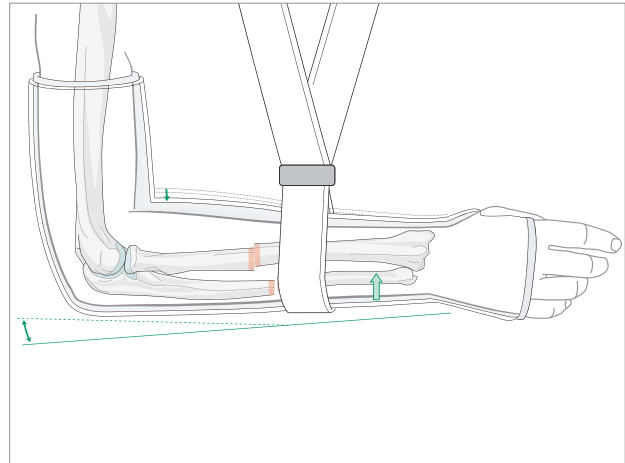
The position of the ulnar fracture should be checked radiographically at 1 week and 2 weeks after the onset of treatment. Should the fracture position become unacceptable, compression plating is indicated.





3.4 Functional bracing

In A1.2 fractures and other relatively simple adult forearm shaft fractures which have had to be treated non-operatively and which have not displaced on follow-up x-rays, functional bracing might be considered, as a means of enhancing rehabilitation.



3.5 Change of treatment method

In occasional cases in which nonoperative treatment was initially indicated for soft-tissue or general medical reasons, the patient's status may improve to the point that operative treatment can be reconsidered. Such a decision will need to be made within 3 weeks of injury, beyond which stage satisfactory reduction of such fractures is unlikely to be feasible.

