



## 4 Tibial and malleolar fractures

### 4.13 I Distal tibial fractures – Treatment with a cast

Indication **43-A, 43-B, and 43-C1 type fractures**

#### 1 General considerations

Definitive nonoperative treatment with a cast is only exceptionally indicated for distal tibia fractures. The nonoperative treatment may, however, be adequate in non- or minimally displaced fractures that are stable. Exceptionally, high surgical risk may be an indication

for nonoperative treatment in additional fracture types. Stabilizing the fracture in a cast may be used for the initial management until soft-tissue situation allows ORIF. In highly unstable fractures, the cast may be inadequate in order to maintain reduction and correct shortening. Those fractures will preferably be stabilized with an external fixator.

#### 2 Indications for a lower leg cast as definitive treatment

##### 2.1 Indication

###### Indication

- Nondisplaced or minimally displaced fractures with intact soft tissues
- Fractures with acceptable reduction:  
Joint surface: <1 mm intraarticular step and <2 mm intraarticular gap.  
Axial alignment: <5 degrees of varus or valgus and <10 degrees of anterior or posterior angulation.  
Fibular length and width of syndesmosis: <2 mm difference to the opposite, uninjured side

###### Contraindication

- Open soft-tissue damage
- Severe closed soft-tissue damage
- Incongruence of the articular surface  $\geq 2$  mm

###### Advantages

- No operative and no anesthesia risk



###### Disadvantages

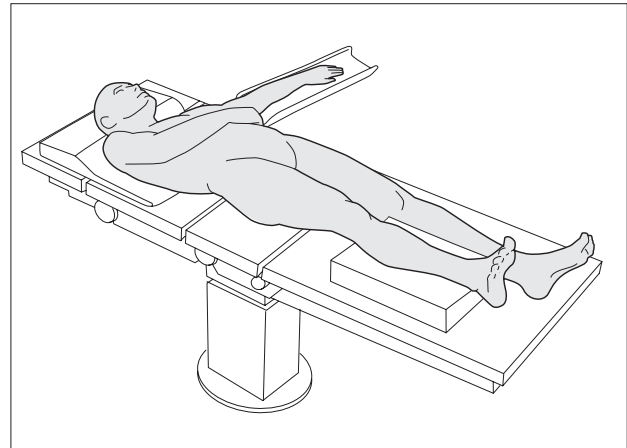
- Inability to monitor soft tissues
- Risk of joint stiffness
- Muscle atrophy
- Risk of thrombosis
- Secondary displacement possible



### 3 Reduction

#### 3.1 Positioning

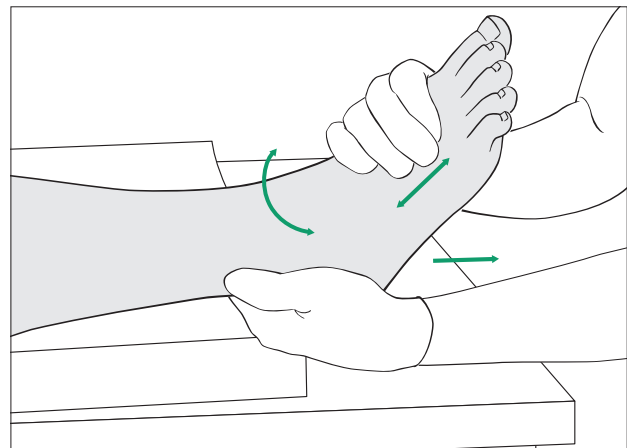
In undisplaced fractures reduction is not necessary. Displaced fractures should be reduced as soon as possible with anesthesia as necessary. The lower leg should be positioned on a pillow so that the heel is slightly elevated from the table.



#### 3.2 Manual reduction

Hold the foot around its middle from plantar and medial. Grasp the heel with the other hand. Reduction is achieved by gentle traction and by alignment of the foot to match the axis of the lower leg, also correcting rotation.

**Note:** After reduction, reconfirm presence of palpable pedal pulses.



### 4 Cast application

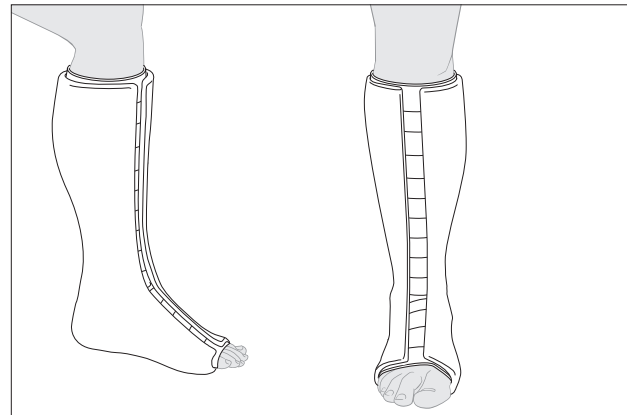
#### 4.1 Principles

Once the fracture has been reduced satisfactorily, reduction must be maintained during cast application by gentle manual and/or gravity traction.

Apply abundant cast padding. This should not be too tight, but may include very gentle compression.

Progressive local soft-tissue swelling must be expected during the first days after injury. Therefore, a closed circular cast is usually contraindicated. The cast may be split and spread anteriorly, or «bivalved» with medial and lateral cuts. Make sure that the splitting provides room for swelling, that the padding is not too tight, and that all bony prominences are decompressed.

Plaster of Paris or fiberglass cast tape can be used. With plaster, the cast must be allowed to harden before splitting is possible.



Be aware that a compartment syndrome can occur even after a cast is split. Make sure the split cast is sufficiently stable to support the fracture.

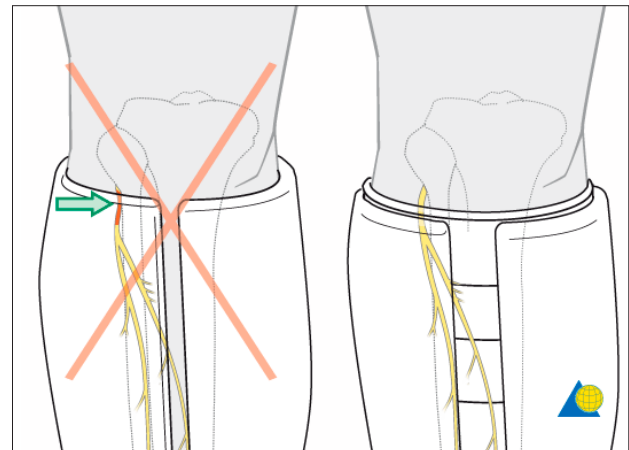




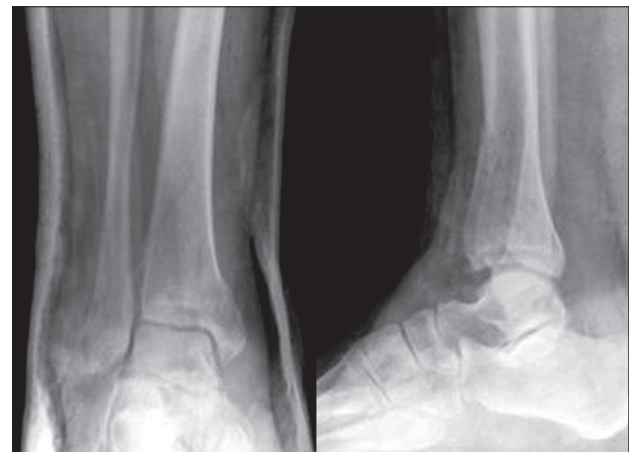
#### 4 Cast application

##### 4.1 Landmarks for cast application and the importance of adequate padding

Proximally, the edge of the cast lies distal to the popliteal fossa. An easy landmark is 3-4 fingerbreadths below the popliteal crease. All toes should be visible dorsally. The common peroneal nerve, superficial to the proximal fibula, may be compressed by the top of a below-knee cast. Adequate padding, and cast molding (posterior flattening and apex anterior angle) help to minimize this risk.



**Note:** After application of the cast, the fracture alignment should be documented radiologically.



#### 5 Aftercare (nonoperative treatment with a cast)

Follow-up x-rays at 3, 7, and 14 days will detect early loss of reduction in cases where final nonoperative treatment is planned. In case of secondary displacement, remanipulation is possible but the fracture situation usually requires additional stability by internal or external fixation.

In cases that are scheduled for final nonoperative treatment, the split cast is changed for a circular cast after

1 - 2 weeks dependent upon the local soft-tissue situation. The circular cast is worn for another 4 - 5 weeks.

Weight bearing is not allowed during the period of cast immobilization.

After 6 weeks, progressive weight bearing is initiated over a period of 4 - 6 weeks. Thrombosis prophylaxis is necessary until full weight bearing is achieved.