



## 5 Acetabular fractures

### 5.11 I Acetabular fractures – Nonoperative treatment

#### 1 Introduction

##### 1.1 Indications for conservative treatment

As a general rule, acetabular fractures are articular fractures, so they have to be treated under the principles of anatomical reduction, stable internal fixation, and early mobilization.

However, there are limited indications for conservative treatment:

- Medical contraindications
- Pre-existing osteoarthritis
- Local infections
- Osteopenia of the innominate bone
- Special fractures characteristics
  - Undisplaced fractures
  - Very low transverse or anterior column fractures
  - Both column fractures that achieve secondary congruence.

##### 1.2 Contraindications to nonoperative treatment

- Step bigger than the width of the cartilage
- Gap bigger than width of the cartilage
- Marginal impaction
- Fracture that involves 20% of the surface of the weight-bearing area.
- Increasing of 20% of the circumference of the acetabulum at the equator of the femoral head.

##### 1.3 Amount of incongruity

Contraindications to nonoperative treatment, and thus indications for surgical treatment, are instability and incongruity.

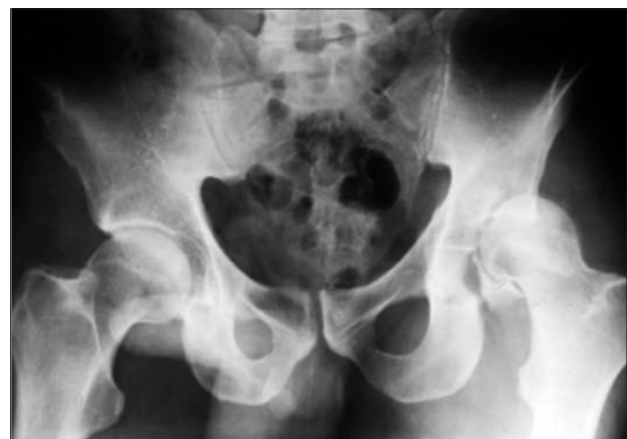##### A. Instability

Hip dislocation associated with

- Posterior wall or column displacement.
- Anterior wall or column displacement.

##### B. Incongruity

- Fractures through the roof or dome
- Displaced dome fragment
  - Transverse or T-types (transtectal)
  - Both column types with incongruity (displaced posterior column)
- Retained bone fragments
- Displaced fragments of the femoral head
- Soft tissue interposition.





### 1.4 Stability of the fracture

Stability is determined by a roof arc measurement.

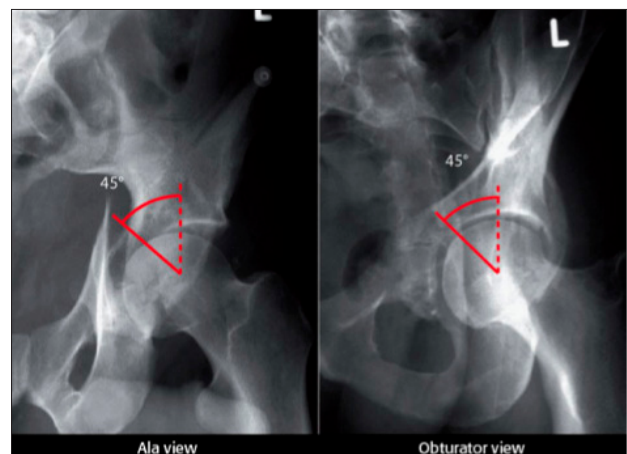
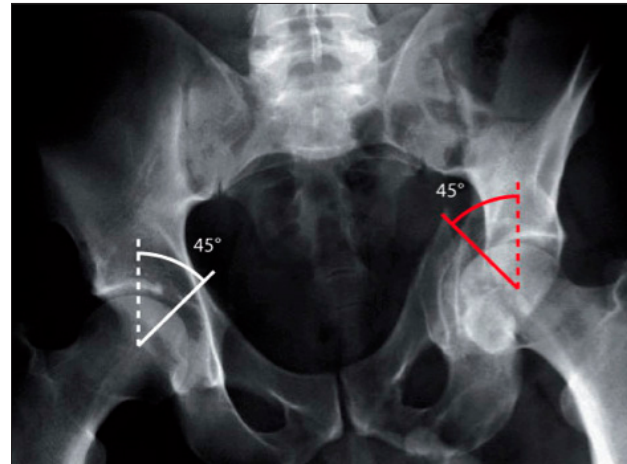
The roof arc angle is determined in the following way:

1. Three radiographic views are needed: AP view, ala and obturator views. Begin by drawing a vertical line through the center of the acetabulum (or the center of the reduced femoral head) on each radiographic view.
2. Now add a second line, intersecting the first at a 45 degree angle at the level of the femoral head's center.

If the second line is outside of the fracture zone in each of the 3 radiographic views, the fracture is considered stable.

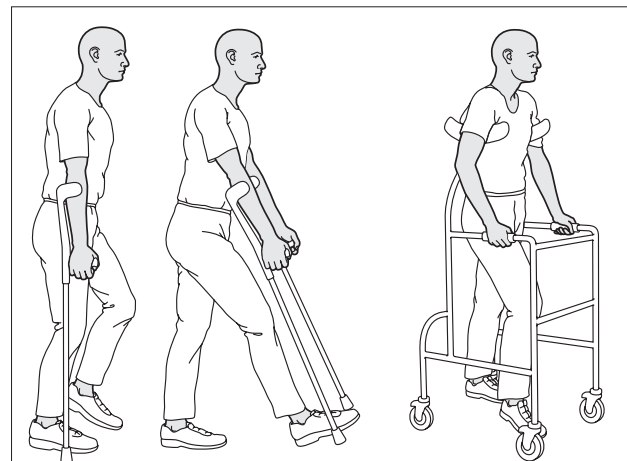
Our example shows a fractured weight-bearing dome of the left acetabulum, with the second line well within the fracture zone, indicating instability.

These images show corresponding measurement of the roof arc on ala (left) and obturator (right) views.



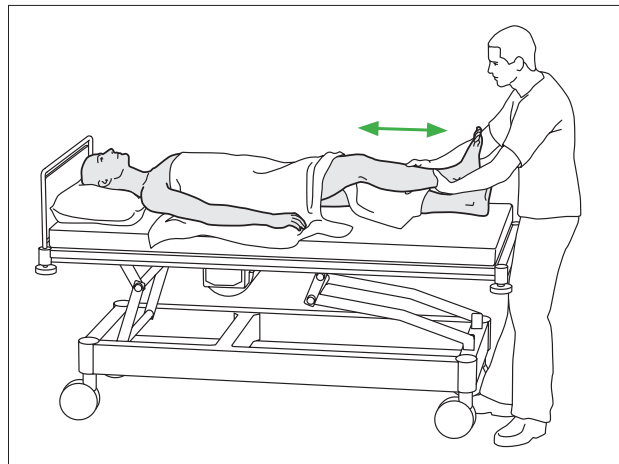
## 2 Undisplaced fractures

After 6 weeks the iliac bone is completely healed. During the period after fracturing, patients are allowed to mobilize with crutches or a walker, as soon as pain is released. Usually that happens after a few days of bed rest. Anticoagulation therapy is established during this period. Once the fracture is healed, no further assistance is necessary.



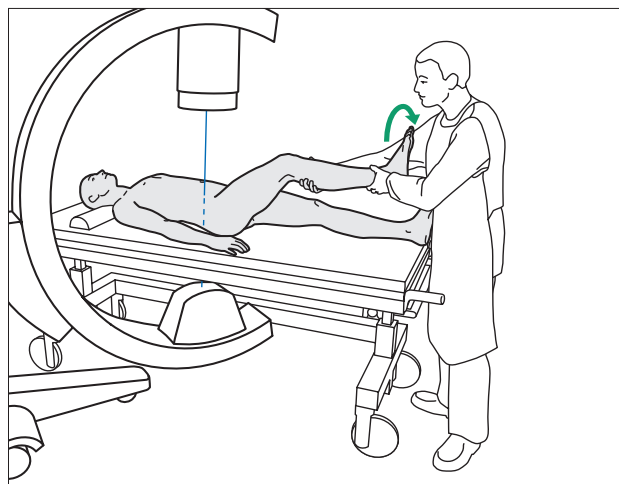


Functional therapy  
Passive assisted and active range of motion are encouraged from the very beginning.



### 3 Displaced fractures

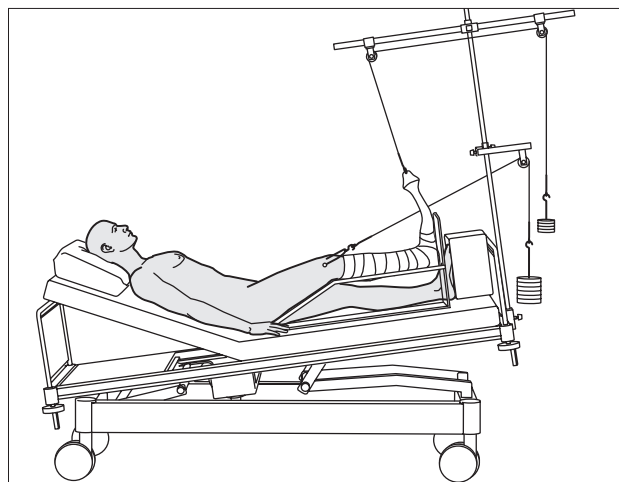
Reduction  
Closed reduction is attempted after hip dislocation.



Skeletal traction

If for any reason the residual amount of displacement is less than indicated for surgical procedure, or there is any contraindication to it, the patient could be put under supracondylar skeletal traction. Usually the tractional weight is 1/7 of the body weight.

Skeletal traction has to be sustained for 6-8 weeks in acetabular and in bony pelvic injuries.





Functional therapy

After completing the skeletal traction, Passive assisted and active range of motion are encouraged.

Some patients after such a long period in traction require the use of a continuous passive motion machine to increase the range of motion.

Even possible to put the patient in skeletal traction, there are many complications related with the bed resting time, such as pulmonary problems, decubitus ulcers, deep vein thrombosis, that have to be addressed.

Final results are in many cases unpredictable.

