



7 Fractures of the foot

7.14 I Fractures of the phalanges — Treatment by buddy taping

Indication **Closed fractures of the 2nd - 5th row without serious displacement**

1 Indication for nonoperative treatment

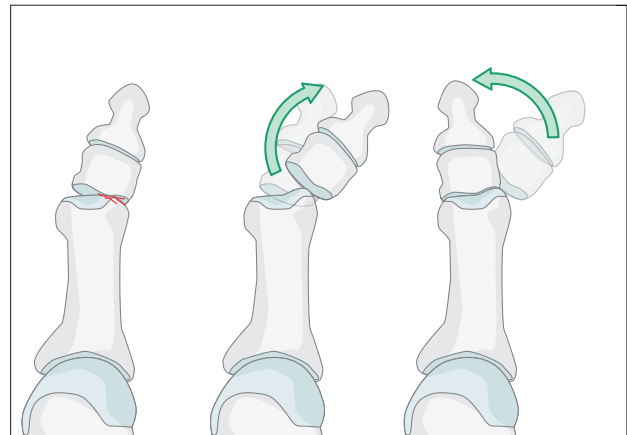
If it is a closed injury and there is no serious displacement, the toe is best treated by strapping it to the

adjacent uninjured toe (buddy taping).

Surgical stabilization is necessary when the fractures are open or grossly displaced.

2 Reduction

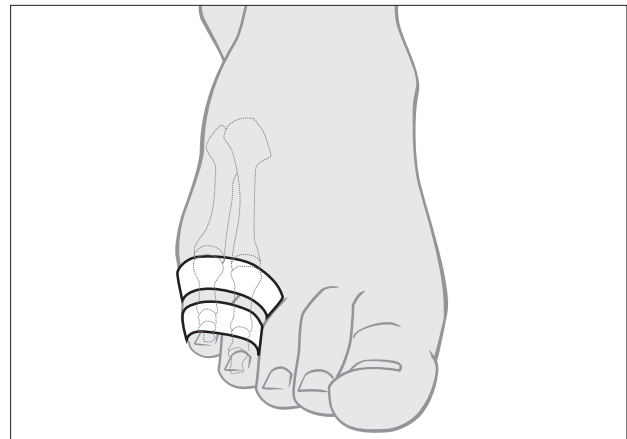
If a toe is dislocated, it is reduced by exaggerating the deformity and then applying traction and reversing the mechanism of injury.



3 Treatment

Alignment can be maintained by buddy taping. The skin is cleaned with alcohol to remove oils and 5-10 mm wide straps are fixed in a loop around the toes. Gauze may be placed between the toes to avoid maceration of the skin.

The MTP joint must be immobilized in an anatomical position to avoid a dorsiflexion contracture.





4 Aftercare

A stiff soled orthosis like a rocker-bottom sandal is used to protect the reduction and allow healing. The symptoms usually settle over the first few weeks. The tape should be changed frequently to prevent maceration between the toes. Most patients are capable of doing this themselves. Taping can be abandoned after 4-5 weeks.

